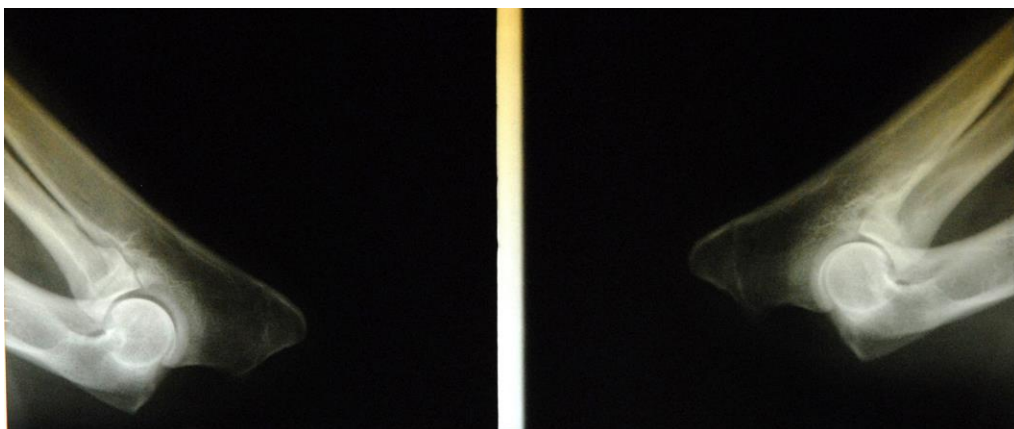
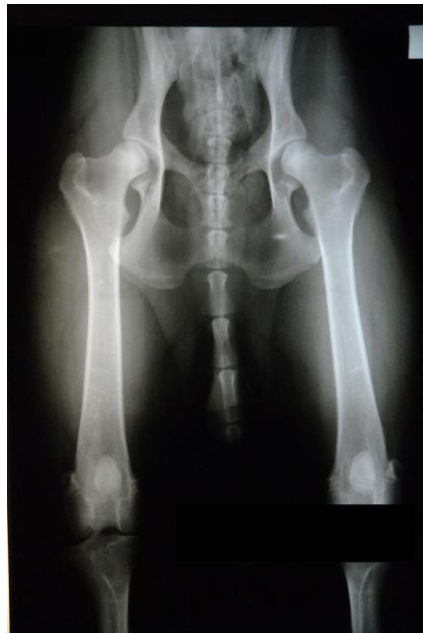

LONG HAired GERMAN SHEPHERD RECEIVES THREE DIFFERENT OFA HIP RATINGS!!

BY KELLY PEET | PUBLISHED OCT 31 2016

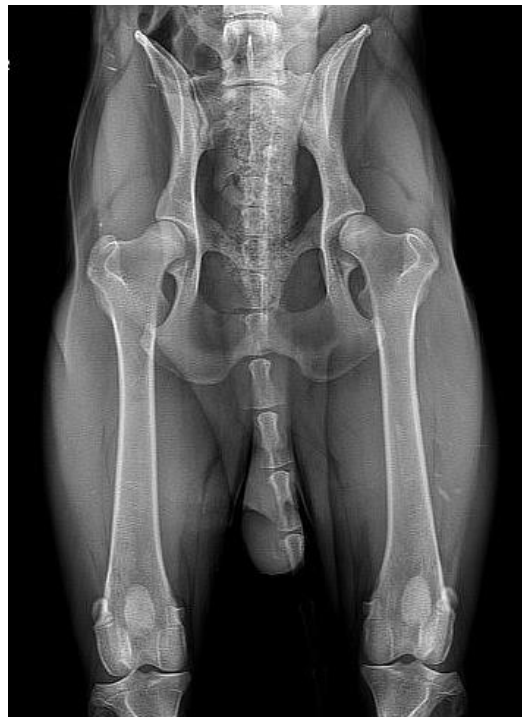I bought an expensive 18 month old import working line long haired (long coat) German Shepherd adult male for many thousands of dollars. This dog had a very impressive pedigree loaded with generations of titles and certified hips. He also had a Pre-lim Good hip rating and normal ratings on his elbows (I can't remember if this was through the vet or the OFA). Below are the Prelim X-rays.



These ratings can change in dogs prior to the age of 2 years old, and that is why the OFA requires the dogs to be 2 years old for the official rating.

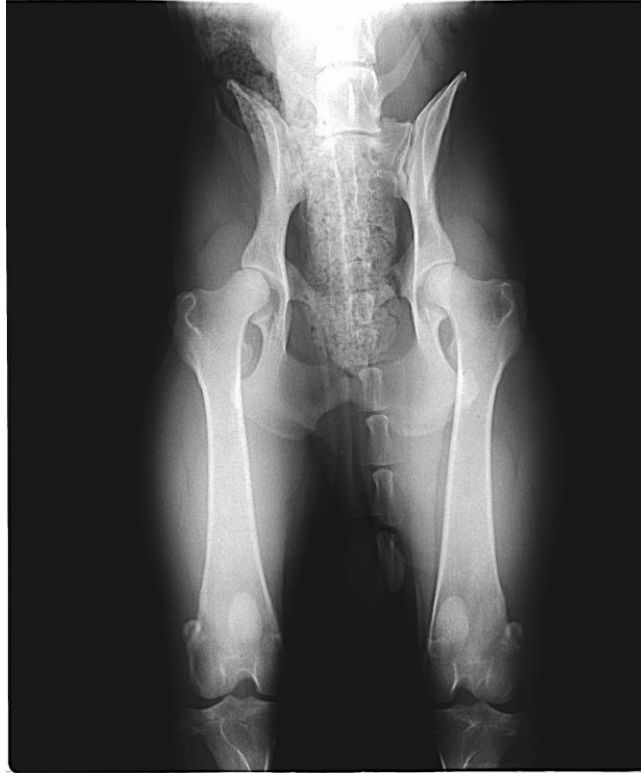My goals were to use this long haired German Shepherd as a stud dog, and of course I wanted to do the right thing and make sure he didn't have hip dysplasia, so I took him to my local vet for OFA hip and elbow x-rays. This procedure cost me about \$400.

About a month later my OFA results came back, and supposedly my dog had Mild hip dysplasia. I was devastated since it had taken me almost a year to find this dog. I did research on the Internet, studied his hip x-rays, and had suspicions that he had not been lined up properly for the x-rays and appeared crooked to me. Below is the x-ray where the dog acquired an OFA MILD HIP DYSPLASIA CERTIFICATION.



**OFA Mild Hip Dysplasia X-rays for a long coat (long haired)
German shepherd**

So I took him to a second local vet, who charged me approximately another \$400. He took x-rays and said my dog had Mild Hip dysplasia and it wasn't worth sending the x-rays to the OFA.

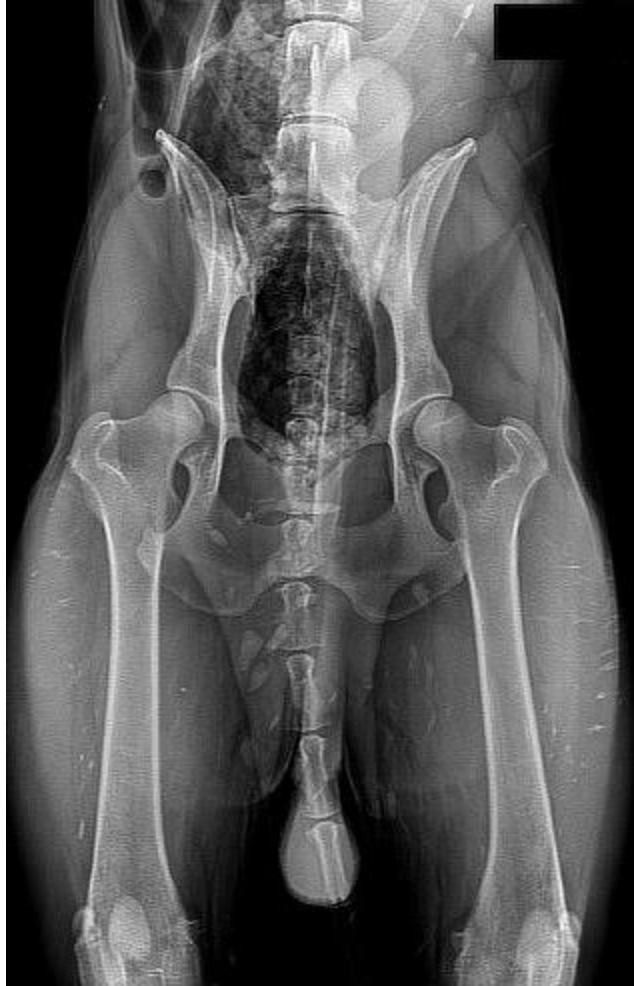

X-Ray above was taken by my 2nd Vet who said that my long haired (long coat) German shepherd had Mild Hip Dysplasia.

At this point I was very distraught. I went home, and reviewed the dogs prelim OFA x-rays where he had received a Good rating, and then I reviewed the second and third set of x-rays taken by two different vet hospitals. I believed he was crooked in the x-rays, and you can't get a Good OFA rating if a dog is crooked.

I called the first vet I had used to x-ray him, and told him that I thought my dog was crooked in the x-rays and that is why he didn't get a good OFA rating. The vet disagreed with me and thought the dog was positioned fine, but agreed to do a second set of x-rays to send to the OFA. If the dog was rated with Hip dysplasia a second time, then I'd owe him the expense of the x-rays and OFA fees.

So we took a second set of X-rays and he was still crooked in them. The OFA rated him as having FAIR hips with no hip dysplasia, and the vet didn't charge me for the second procedure. This was my THIRD TIME I had this poor boy x-rayed by vets for the OFA submission! Below are the x-rays that the dog received an OFA fair rating for.



SAME LONG HAIRD GERMAN SHEPHERD DOG – X-RAYS RECEIVE AN OFA FAIR HIP RATING

But I still was not satisfied. I felt that this dog had Good hips, but didn't want to waste any more money on vets who didn't know how to properly position the dog.

A few months earlier I had questioned a man driving a van with hunting show dogs at a WV convenience store. I liked his van and asked him if I could see inside. During our conversation he told me that he had driven from NY (if I remember correctly) to OH to have his dogs x-rayed for the OFA certifications. He also mentioned going to a field trial to show his dogs. This meeting happened prior to me having so many problems getting my dog properly x-rayed, so I didn't think to ask him why he was driving his dogs so far for OFA X-rays. He was in a hurry so our conversation was pretty short. But he did give me a real estate business card.

After my dog received the OFA Fair rating on hips, I decided to try and track down the vet that the breeder from NY drove to see in OH. The number on the business card was bad, I had a terrible time tracking down his kennel, but after several days I was successful. Once I contacted the kennel they gave me the vet hospital's name. It was **Troy Animal Hospital in Troy OH.**

I contacted Dr. Davis and emailed him my X-rays and he reviewed them for a modest fee. After he had reviewed the x-rays, he thought that my dog might have OFA GOOD hips and that he was improperly positioned in the X-rays.

So I rented a van, loaded up about 3 of my dogs including the one who kept being X-rayed crookedly, and made a 8 hour round trip journey to Troy OH.

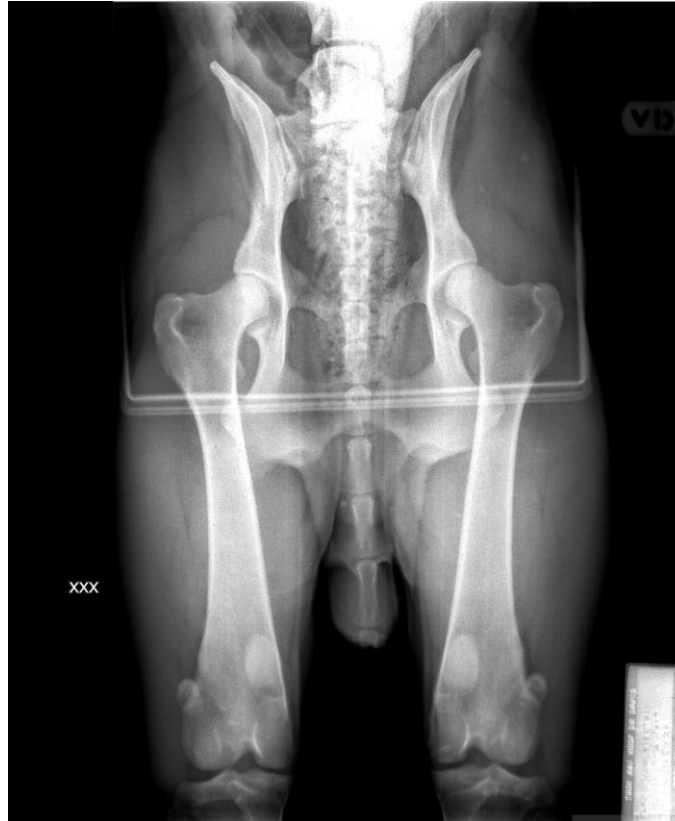Once there, Dr. Davis and his crew were wonderful with my dogs. He believes that un-sedated dogs get better results, so two of my dogs were X-rayed un-sedated. Unfortunately the dog who was getting the bad X-ray results was the one we had to sedate because he would not co-operate.

After we finished the x-rays, I loaded up my dogs and drove home with high hopes that everyone would get OFA Good ratings now that they had been properly aligned and X-rayed.

I anxiously awaited the OFA results, and probably pestered the OFA with my phone calls due to my impatience. I also checked the website daily. (By the way...OFA results can also be found by using the Search options on the OFA website, but the OFA doesn't always post all results because the owner has the right to block confirmed dysplasia results being made public. That may be why some dogs are only shown with a OFA hip or elbow ratings, but not both ratings. Usually if someone wants to get a dog OFA certified, they have both the hips and elbows done at the same time due to the expense of the procedure and in order to breed or show the dogs.)

Anyway, to my great joy...all three of my dogs passed the OFA Hip and Elbow ratings! No hip dysplasia! The dog that began this whole ordeal...ended up getting a OFA GOOD Hip rating! So these are all the ratings that this dog acquired during this ordeal.

Below is the x-ray where he acquired an OFA Good rating on his hips.



OFA Good Hips X-rays for a long haired (long coat) German Shepherd

So to sum this up. One dog...the **SAME** dog...has received THREE different OFA RATING CERTIFICATIONS. **1st – Mild hip dysplasia, 2nd- Fair Hips, 3rd – Good hips.** I sincerely believe that these different ratings were due to positioning during the x-ray procedure.

1st Vet – OFA Prelim X-rays (before he was 2 years old) – Hips Good – Elbows Normal

2nd Vet – OFA X-rays at 2 years old – Hips Mild Dysplasia – Elbows Normal

3rd Vet – X-rays not submitted to OFA – Hips Mild Dysplasia

4th Vet – OFA X-rays by Dr. Davis at Troy Animal Hospital – Hips Good

Anyway, from that point on I took all my dogs to Dr. Davis even though I had to rent a van and make an all day trip because it was worth it every time.

A local trainer who was aware of the ordeal I went through for the OFA hip rating didn't take my advice and go to Troy for her dog, and instead took the dog to a local vet in my

area (that I had not previously used), but other people had. Her dog came back with a rating of Mild Hip dysplasia.

After getting the bad rating, she decided to take my advice, and took her dog to Troy. After those X-rays were submitted to the OFA, her dog was rated with OFA Fair hips with no hip dysplasia.

Therefore the moral to this story is that I believe most vets do not know how to properly position dogs for hip x-rays. I spent about \$2,000 for an OFA Good hip rating for **ONE DOG** due to my local vets not knowing how to properly align my dog. Once I found a vet who knew what he was doing my dogs received OFA hip and elbow passing scores.

Even if Dr. Davis is to far for you to travel to, he can review your x-rays and let you know his opinion. If you would like to read more about proper positioning for OFA X-rays, [click here](#).

KELLY PEET'S STORY ON OFA HIP DYSPLASIA, X-RAYS, AND RATINGS by Kelly Peet.

THIS ENTRY WAS POSTED IN DOGS, DOGS - GERMAN SHEPHERDS, DOGS - GERMAN SHEPHERDS - LONG COAT, DOGS - GERMAN SHEPHERDS - LONG COAT - ADULTS, DOGS - GERMAN SHEPHERDS - LONG COAT - BREEDERS, DOGS - GERMAN SHEPHERDS - STANDARD COAT, DOGS - GERMAN SHEPHERDS - STANDARD COAT - ADULTS, DOGS - GERMAN SHEPHERDS - STANDARD COAT - PUPPIES, DOGS - HEALTH, DOGS - HEALTH - HIP DYSPLASIA AND TAGGED CANINE HIP DYSPLASIA, DOG HIP DYSPLASIA, GERMAN SHEPHERD HIP DYSPLASIA, HIP DYSPLASIA, HTTP://KELLYPEET.COM, KELLY PEET, LONG COAT GERMAN SHEPHERD HIP DYSPLASIA, LONG COATED GERMAN SHEPHERD HIP DYSPLASIA, LONG HAIR GERMAN SHEPHERD HIP DYSPLASIA, LONG HAIRE GERMAN SHEPHERD HIP DYSPLASIA.
« LONG HAIRE (LONG COAT) GERMAN SHEPHERD ADULTS PHOTO GALLERY H1
HIP DYSPLASIA by TROY ANIMAL HOSPITAL »